

Interceptive orthodontic treatment with elastodontic appliance for open bite in early childhood: a case series

Filippo Vena¹
Giorgia D'Amico¹
Filippo Cardarelli²
Stefano Cianetti¹
Marco Severino¹

¹School of Medicine, Department of Medicine, Odontostomatological University Centre: Chair Prof. Stefano Cianetti, University of Perugia, S. Andrea delle Fratte, Perugia, Italy

²Department of Interdisciplinary Medicine, University of Bari "Aldo Moro", 70124 Bari, Italy

Corresponding author: Filippo Vena
email: f.vena@unipg.it

Abstract

This case series explores the effectiveness of interceptive orthodontic treatment using A.M.C.O.P elastodontic appliances for open bite correction in early childhood. The study included three patients aged 3-5 years with primary dentition open bite and associated oral habits, treated at the Odontostomatological Centre, University of Perugia. Treatment utilized A.M.C.O.P Bio-Activators, tailored for early intervention, leveraging light, biological elastic forces to guide jaw growth and correct dental alignment.

The study highlights the role of timely intervention using A.M.C.O.P Bio-Activators in managing malocclusions, demonstrating significant improvements in occlusion and functional disorders. Early treatment with these devices not only corrects open bite efficiently but also reduces the need for future orthodontic interventions, emphasizing the importance of accurate diagnosis and patient compliance in achieving lasting results.

Introduction

During growth the occlusion is determined by the position of the teeth and the disposition of the facial bones and, as has been demonstrated, the dimensional growth of the oral cavity from childhood to adolescence is not able to correct the majority of the malocclusion traits of the primary dentition phase (1). Interceptive orthodontic treatment is essential to guide these processes. It is possible to correct malocclusion and oral habits with A.M.C.O.P Bio-Activators. These are removable elastodontic devices that influence jaw growth, guide the position of the teeth and solve functional disorders using light and biological elastic forces. They are suitable for primary dentition, mixed dentition and for adults with complete permanent dentition (2-5).

Aim of this report is to describe interceptive orthodontic treatments with A.M.C.O.P elastodontic appliances of patients in primary dentition with open bite, a vertical plane malocclusion which can be determined by genetic and skeletal causes, but also by spoiled habits like prolonged thumb-sucking or incorrect tongue position (6).

In this cases, the objectives of treatment were to correct the open bite, to obtain a correct overbite and overjet, to improve aesthetical conditions and to maintain clinical results in time.

The cases shown are children in primary dentition aged <6 years. This article presents three cases of open bite corrected by using A.M.C.O.P elastodontic devices

Materials and methods

The three cases selected for our report are patients from the Odontostomatological Centre University of Perugia. They satisfied the following selection criteria: 3-5 years of age, primary dentition, with open bite and oral habits, and no history of previous interceptive orthodontic treatments.

Authors

Filippo Vena- School of Medicine, Department of Medicine, Odontostomatological University Centre: Chair Prof. Stefano Cianetti, University of Perugia, S. Andrea delle Fratte, Perugia, Italy

Giorgia D'Amico - School of Medicine, Department of Medicine, Odontostomatological University Centre: Chair Prof. Stefano Cianetti, University of Perugia, S. Andrea delle Fratte, Perugia, Italy

Filippo Cardarelli - Department of Interdisciplinary Medicine, University of Bari "Aldo Moro", 70124 Bari, Italy

Stefano Cianetti - School of Medicine, Department of Medicine, Odontostomatological University Centre: Chair Prof. Stefano Cianetti, University of Perugia, S. Andrea delle Fratte, Perugia, Italy

Marco Severini - School of Medicine, Department of Medicine, Odontostomatological University Centre: Chair Prof. Stefano Cianetti, University of Perugia, S. Andrea delle Fratte, Perugia, Italy



License

This work is licensed under a [Creative Commons Attribution-NonCommercial-NoDerivatives 4.0 International License](https://creativecommons.org/licenses/by-nc-nd/4.0/).

Authors contributing to Oral and Implantology agree to publish their articles under the [Creative Commons Attribution-NonCommercial-NoDerivatives 4.0 International License](https://creativecommons.org/licenses/by-nc-nd/4.0/), which allows third parties to copy and redistribute the material providing appropriate credit and a link to the license but does not allow to use the material for commercial purposes and to use the material if it has been remixed, transformed or built upon.

How to Cite

Filippo Vena, Giorgia D'Amico, Filippo Cardarelli, Stefano Cianetti, Marco Severino.

Interceptive orthodontic treatment with elastodontic appliance for open bite in early childhood: a case series
Oral and Implantology, 15(1), 25-28.

Case 1

A 3 years old female patient with a history of prolonged thumb sucking came at our clinic. On clinical examination, dental open bite, atypical swallowing and upper arch contraction were noticed (Figure 1). The open bite was treated with A.M.C.O.P elastodontic devices: DC Bio-Activator (with pacifier grip) for 6 months (used such as her old pacifier) (Figure 2), A.M.C.O.P Open for almost 12 months (Figure 3): on the first 5 months one hour per day and for all night, and then only on nights. Interceptive therapy was supported by motivation and miofunctional therapy

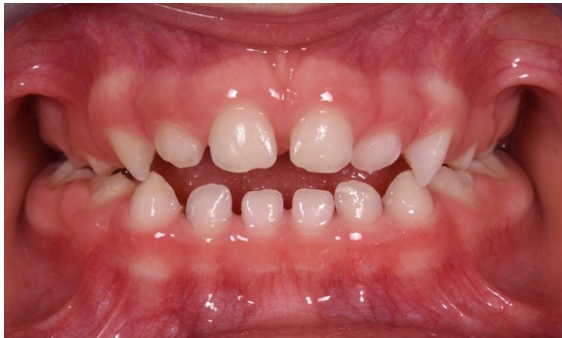

Figure 1.

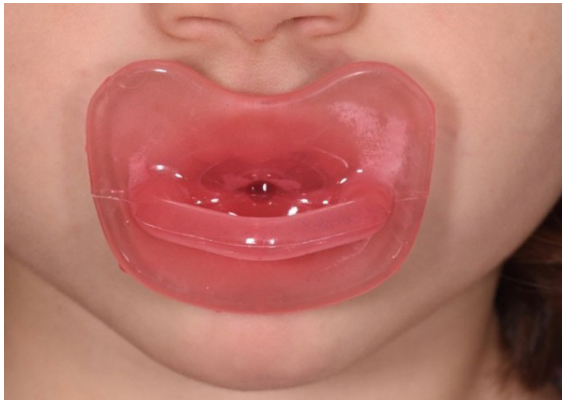

Figure 2.

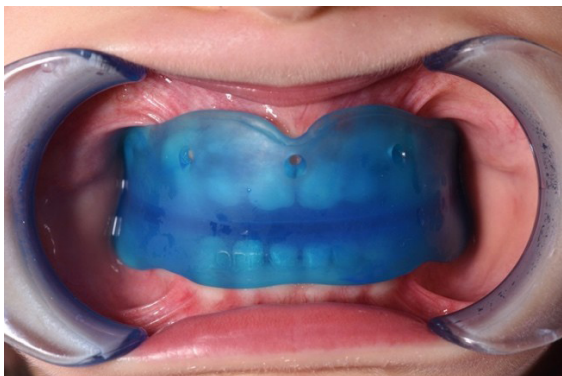

Figure 3.

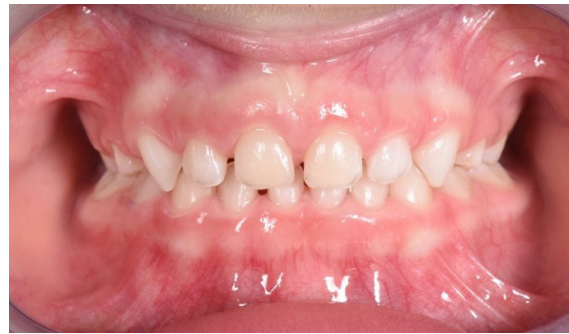

Figure 4.

Case 2

A 4 years old male patient with a short lingual frenulum and a difficulty to leave the pacifier came at our clinic. The clinical examination reported a dental open bite, which was treated with

A.M.C.O.P Open for almost a year (Figure 6), one hour per day and all night. We chose to start directly with the Open due to the skeletal open bite of his mum (so he had familiarity for this malocclusion). He was also motivated to follow the treatment, which was matched with speech therapy.

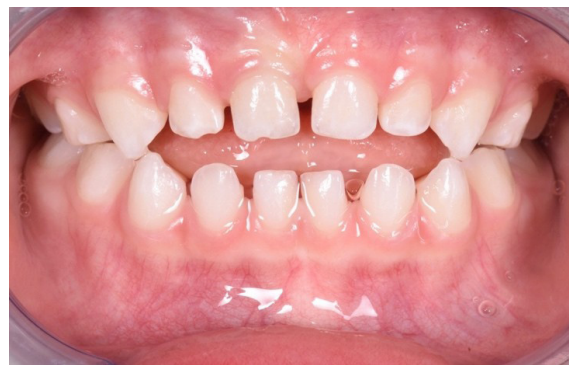

Figure 5.

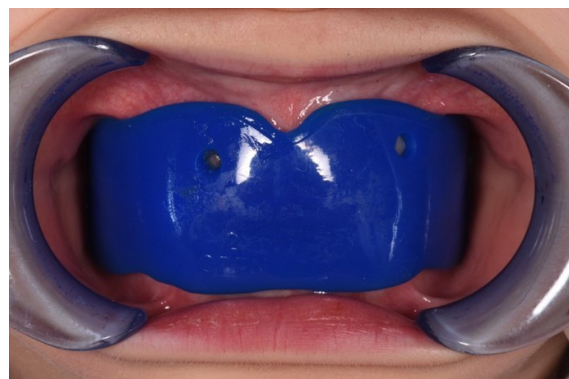


Figure 6.

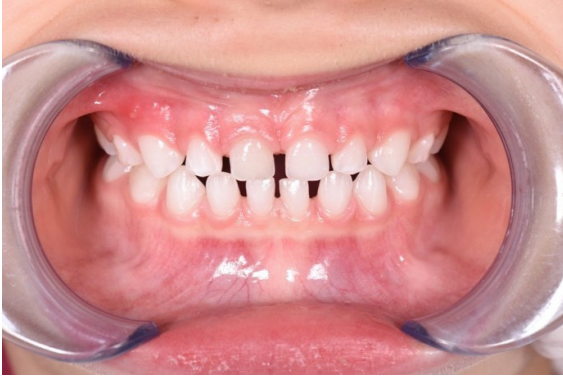

Figure 7

Case 3

A 3 years old male patient with light skeletal class III malocclusion, open bite, atypical swallowing, contraction of upper arch, tendency to class III. On clinical examination a short vestibular frenulum was noticed (by pulling the upper lip, it tended to become ischemic, such as the retroincisive papilla (Figure 8). In these kind of situations also waiting can be considered, but due to the necessity of an orthodontic therapy we chose to perform a frenulectomy, and on the same day we made the patient wear the TC elastodontic device (Figure 10). The vestibular shield of the appliance contributed to the healing of the frenulum by determining continuous traction of the upper lip.

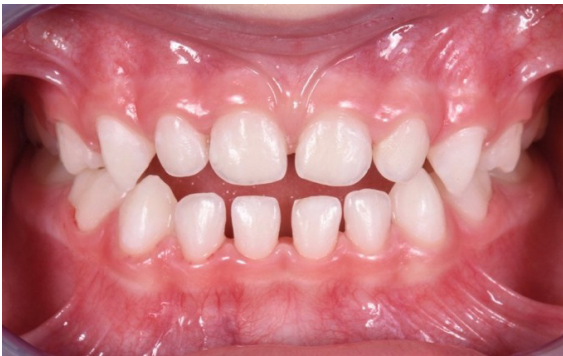

Figure 8.

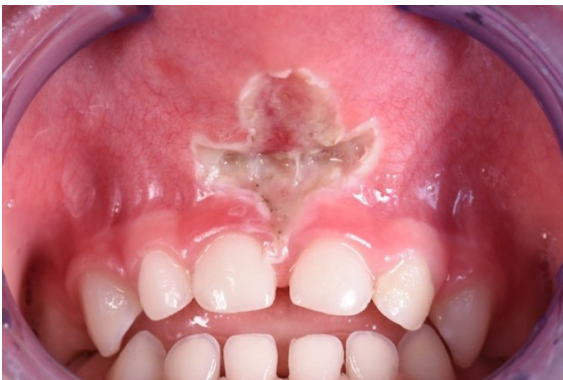

Figure 9.

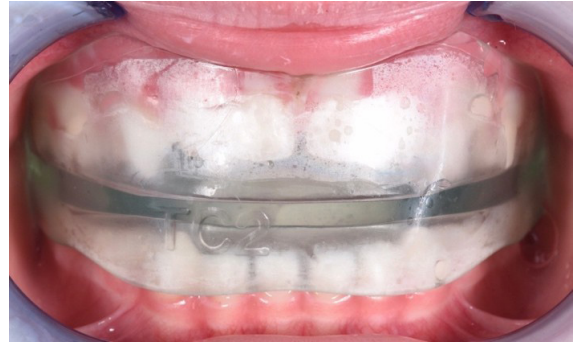

Figure 10.

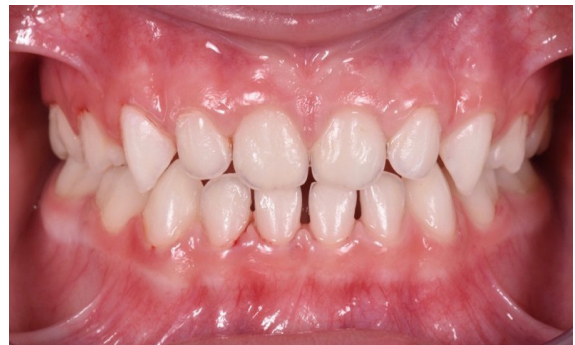

Figure 11.

Discussion

In the three cases previously described the open bite was solved in 12-18 months by A.M.C.O.P bio-activators devices. Timing was crucial for the success of these preventive treatments

A.M.C.O.P Bio-Activator Devices

These devices have an arch harmonizing function and are characterized by different colors, letters and numbers for each malocclusion: first, second and third class and also for young children in primary dentition, pacifier-like devices for early and interceptive treatment, considering that dental movement in young children is simple, because the periodontal fibers are still immature (3).

The absence of indentation allows the contemporary reposition of both dental arches by a multidimensional orthopedic action. This is accompanied by the correction of the oro-pharyngeal neurovegetative functions (such as the correct posture of the tongue at rest, the correct swallowing and nasal breathing in oral respirators), which makes the treatment results more stable over time (7- 10).

Bio-Activator for young children

Bio-Activators for very young children D and DC (Figure 2), with "pacifier" grip are used in primary dentition with a functional and orthopedic-osteopatic action. They are indicated for different arch discrepancies, deviations, bilateral and monilateral crossbite, transverse deficit, and open bite due to prolonged use of the pacifier. It is ideal to replace the pacifier, stimulating the correct growth of

the jaws, for arch expansion, and to solve dysfunctional oral habits, correct tongue position, improve swallowing and nose breathing in oral respirators, night grinding, thumb sucking (3).

The Open Bio-Activator

The Open Bio-Activator is indicated for anterior open bite malocclusion, caused by spoiled habits like atypical swallowing. This device provides an orthodontic-orthopedic action, releasing of certain skeletal craniofacial structures in anterior flexion movement with the restoration of the occlusal plane (11-12).

Third Class (TC) Bio-Activator

TC (Figure 5) is indicated for the treatment of third class dysmorphism by positioning the upper teeth in an anterior sliding plane, while it exerts a posterior pressure on the lower arch, for a braking action of mandibular growth. The functional, orthopedic-osteopathic action allows the correction of: third skeletal classes by repositioning the dental arches in a first class key, arches deviation, spoiled dysfunctional habits, tongue position, reverse and anterior open bites, improving swallowing and nasal breathing in oral respirators (3).

Conclusion

The AMCOP Bio-Activators used to treat these three clinical cases of Open Bite showed effectiveness to achieve therapeutic targets, representing valid aids for early interceptive treatments with several advantages: correction of open bite in a limited treatment period (18-20 months) by reconditioning the natural growth forces of neuro-musculo-skeletal system, low impact on patients' compliance since the thermoplastic material makes these devices elastic, comfortable and suitable for any dental arch conformation (3;13).

Early interceptive treatment is fundamental to avoid future problems that a malocclusion, in this case an open bite, can create, reducing the possibility of orthodontic fixed appliances, and to achieve good results is essential, apart from patient's compliance, to carefully focus on the dentition and occlusion development, to provide an accurate diagnosis, choosing the right time and the right devices to start the treatment (14).

References

1. Lombardo, G.; Vena, F.; Negri, P.; Pagano, S.; Barilotti, C.; Paglia, L.; Colombo, S.; Orso, M.; Cianetti, S. Worldwide Prevalence of malocclusion in the different stages of dentition: A systematic review and meta-analysis. *Eur. J. Paediatr. Dent.* 2020, 21, 115–122.
2. Rollet D, Graindorge JC, Guenzennec P. A new concept: elastodontics. *Rev Orthop Dento Faciale* 1991; 25(2):149-167.
3. Cardarelli F., Il Trattamento Funzionale elastodontico con apparecchi AMCOP : Funzione, Estetica e postura. *Dental Tribune, Italian edition, Giugno 2019*
4. Cardarelli, F. Cardarelli, A. Il laser in elastodonzia. *Doctor Os*, 2021
5. Inchingolo, A.D.; Ceci, S.; Patano, A.; Inchingolo, A.M.; Montenegro, V.; Di Pedè, C.; Malcangi, G.; Marinelli, G.; Coloccia, G.; Garibaldi, M.; et al. Elastodontic Therapy of Hyperdivergent Class II Patients Using AMCOP® Devices: A Retrospective Study. *Appl. Sci.* 2022, 12,3259.
6. Negri, P.; Vena, F.; Lomurno, G.; Coniglio, M.; Cianetti, S.; Gatto, R.; Severino, M. Index of Orthodontic Treatment Need (IOTN) and distribution of malocclusion traits in a population of growing patients attending a public orthodontic service in Perugia (Italy). *Eur J Paediatr Dent.* 2021, 22(4), 303-308.
7. C. İlisulu, S. Uz, M. Koruyucu, F. Seymen, Early Interceptive Orthodontic Treatments: Case Series. *Int J Med Invest* 2019; Volume 8; Number 3; 104-111
8. G. Laganà, P. Cozza. Interceptive therapy with elastodontic appliance: case report. *Annali di Stomatologia* 2010; I (3-4): 22-28
9. Inchingolo, A.D.; Patano, A.; Coloccia, G.; Ceci, S.; Inchingolo, A.M.; Marinelli, G.; Malcangi, G.; Montenegro, V.; Laudadio, C.; Pedè, C.D.; et al. The Efficacy of a New AMCOP® Elastodontic Protocol for Orthodontic Interceptive Treatment: A Case Series and Literature Overview. *Int. J. Environ. Res. Public Health* 2022, 19, 988
10. Cardarelli F., Pascetta R., *Estetica Dentale Eccellente, Quintessenza Odontotecnica* 2017; 2.
11. Aranitasi L, Tarazona B, Zamora N, Gandía JL, Paredes V. Influence of skeletal class in the morphology of cervical vertebrae: A study using cone beam computed tomography. *Angle Orthod.* 2016 Aug 11.
12. Patano, A.; Inchingolo, A.M.; Cardarelli, F.; Inchingolo, A.D.; Viapiano, F.; Giotta, M.; Bartolomeo, N.; Di Venere, D.; Malcangi, G.; Minetti, E.; et al. Effects of Elastodontic Appliance on the Pharyngeal Airway Space in Class II Malocclusion. *J. Clin. Med.* 2023, 12, 4280.
13. Torsello, F., D'Amico, G., Staderini, E., Marigo, L., Cordaro, M., & Castagnola, R. (2022). Factors Influencing Appliance Wearing Time during Orthodontic Treatments: A Literature Review. *Applied Sciences* 12, 7807-7807.
14. Viazis A.D. Efficient orthodontic treatment timing. *Am J Orthod Dentofacial Orthop* 1995; 108(5):560-1.